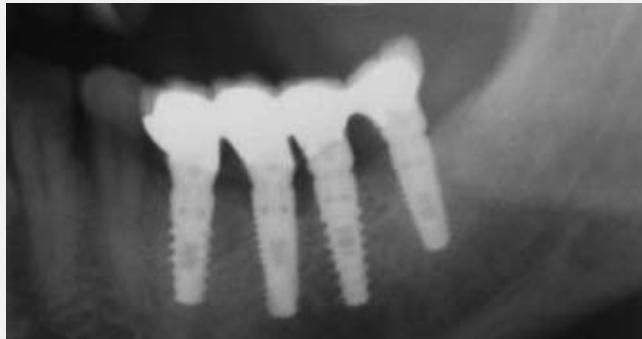


19

News No.19, July 2007

Study of bone level
around osseointegrated
dental implants

- One year followup



mis
Make it Simple

Study of bone level around osseointegrated dental implants

Prof. Dr. Emanuel Bratu, Dr. Karancsi Olimpiu and Dr. Sita Radu

Victor Babes University of Medicine and Pharmacy, Department of Oral Implantology Timisoara, Romania.

Introduction

Implant dentistry has evolved spectacularly over the last two decades with the number of implants done increasing exponentially in the last few years. The concept of "implant follows bone" was replaced by "bone follows implant and prosthetics". Nowadays, the problem of osseointegration is no longer the issue. Instead, aesthetics and bone loss around dental implants are the main concerns. The questions that patients ask today are no longer: will the implant integrate? and how long is it going to last? The literature reports present survival rates of 98-99% at 5 years, and about 90% at 10 years. But an important question remains: what is the level of bone around the implants? This is of great concern, particularly for younger patients. Today, the rules for getting a stable bone level around implants are clear: sufficient bone (1 mm) and a fixed gingiva around the implant. These conditions can be obtained by augmentation techniques and proper preoperative evaluation. But the design of the implant body and surface structure also plays a major role in an implant's success.

The aim of the present study was to evaluate how implant body design influences the bone level around the implants.

Materials and Methods

Careful patient selection was done to obtain cases with sufficient bone volume to preclude the need for augmentation techniques. Patients were selected according to the following criteria:

- Terminal mandibular edentulism (Kennedy class I and II).
- No chronic diseases in the patients' history.
- Nonsmokers.
- Absence of or controlled periodontal disease.
- Flexibility for review.

Patients ranged from 30 to 65 years of age, with an average age of 46 years. The authors performed all surgical and prosthetic steps. The minimum bone height was about 11mm, so implants of 10 and 11.5 mm were used. Diameters of 3.75 and 4.2 mm were used. The implants were made by MIS Implants Technologies Ltd., Shlomi, Israel, and were type LANCE and SEVEN, fulfilling all European and US requirements.

Seventy-two implants were inserted in pairs, one Seven and one Lance with the same diameter and length, only in mandibular terminal edentations, with adequate bone offer in 28 patients. Eight of the patients received two pair (4 implants) along the distal residual crests, because of the number of missing teeth that needed replacement.

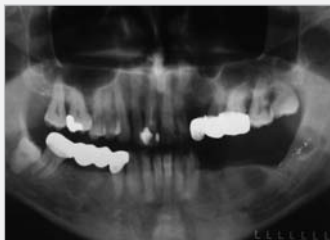The aim of the study was to evaluate bone loss around the two implants after the healing period and 6 months after loading.

The LANCE implant is a classical tapered screw implant with triple lead threads and polished neck, while the SEVEN implant is a new design that incorporates a progressive thread, a rough sand blasting & acid etching surface up to the implant neck and micro rings at the superior part of the implant. This design's supposedly improved bone stability around implants was considered subject to this comparative study.

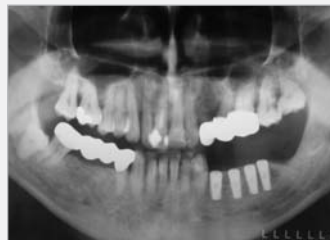The implants were inserted in the same bone quality, using the same diameter, length and platform. Panoramic x-rays were taken with the same device before and after surgery and at the reopening, 4 months later, and also one year after loading. Panoramic X-rays of each patient were taken before and after insertion. 4 months after surgery and 6 months after loading. Retroalveolar x-rays were also taken and bone measurements were made using the metric scale on the MIS radiographic templates and the electronic vernier gauge. Bone loss was measured from the platform on the proximal surfaces of the implant. The registered values are given in Table 1. Periotest measurements taken on insertion and 4 months later are given in Table 2.

Case 1

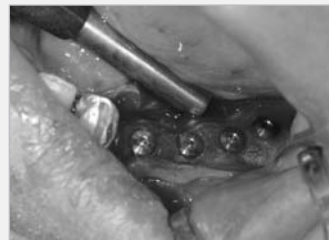Fifty-one-year-old male patient, nonsmoking and with good oral hygiene, presenting terminal lower left mandibular edentulism; received four dental implants of 4.2 mm diameter by 11.5 mm length, two Lance implants in place of 34 and 36, and two Seven implants on place of 35 and 37.



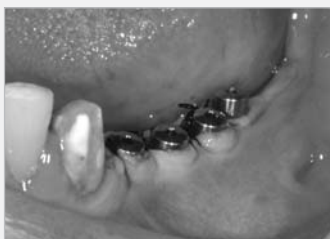Preoperative radiographic evaluation of the patient. Adequate bone offer.



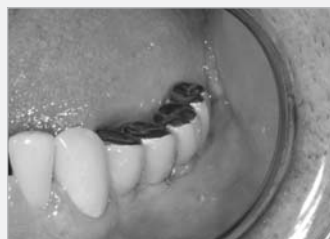Postoperative radiographic image of the implants, diameters 4.20 length 11.5.



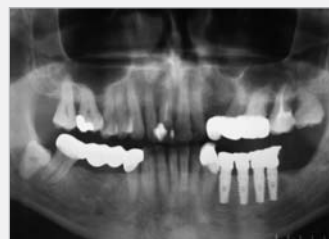Oral view after implant insertion. Note that the implants are completely inserted into the mandibular crest.



Clinical view after 4 months at uncover and the fixation of the healing screws.



Final aspect of the in-situ metal-composite restoration.



Situation after 6 months of loading.

Surgical protocol

A full thickness flap was elevated, and the standard drill sequence for every implant type succeeded. The SEVEN implant was offered with a single use final drill, which prepares the implant bed, to obtain an optimal fit to the bone. Implant stability was measured with the dynamometric wrench and Periostest device. Implant insertion torque was between 30 and 50 Ncm, measured on the MIS torque wrench. Periostest values ranged between 0 and -6 after insertion. Careful verification of the bone level around the implants was performed, to avoid any differences between the implants. A suture was made and postoperative medication was given to the patient (amoxicillin 625 mg every 12 hours, ketoprofen for 3 days and a chlorhexidine solution mouth rinse). The sutures were removed after 7 to 10 days. None of the cases presented serious postoperative complications. Two cases presented small dehiscence and incomplete wound closure, which healed "per secundam". No implant was lost in the healing period.

Prosthetic protocol

The patients had no provisional prostheses. After 4 months, the reopening procedure was performed. No tissue punch was used, but only classic surgical opening. Healing screws were kept in place for 10 to 15 days. Periostest values after four months ranged from -8 to -3. The bone level was measured clinically and with panoramic x-rays. All implants were splinted with cement retained metal-ceramic and metal-composite restorations.

Results

None of the 72 implants failed.

Periostest values

The periostest values ranged from -6 to 0 immediately after surgery and -8 to -3 at the time of uncover.

Bone resorbtion

Bone resorbtion at four months after insertion,

at the time of the second surgery, varied from 0 mm to 1.8 mm for Lance implants and from 0mm to 1 mm for the Seven implant, giving an average of 0.91 mm for the Lance implant and 0.22 mm for the Seven implant. After loading, the bone level dropped to an average of 1.29 mm for the Lance and to 0.63 mm for the Seven.

It is interesting to note that bone resorbtion after four months for the Seven implant was minimal compared to the Lance implant, and after loading, the bone loss continued for both implant types, but with almost double the rate for the Lance compared to the Seven. This suggests that the surface treatment of the whole implant body, and the presence of the micro-rings seem to make a difference. This fact is sustained by the same quality of bone that was present around both types of implants. One year after prosthetic treatment, the bone remodeled in a small amount around the Seven implants and at a bigger rate around the Lance implants.

Discussion

The concept of bone fixation on a rough surface was shown to be feasible a long time ago by numerous clinical studies. It seems that it is no longer necessary to leave a polished neck around two stage implants with subgingival healing. It is well known that bone is more stable around rough surface comparative to polished surfaces.

This is also true for soft tissue that has no problem adhering to rough surfaces as long it is stable and the gingiva is thick and nonmobile. Therefore, it is very important to obtain attached gingiva around the implants in order to have long-term success. All the implants in this study were splinted by superstructures. The restorations were cemented using MIS Crown Set temporary cement.

The maximal bone loss around a Lance implant was 1.7mm, and the minimum was 0 mm. The maximum bone loss around the Seven implants was 0.2 mm. This shows the superiority of the sand blasting & acid etching surface treatment and the improved design of the Seven implants. Also, it is possible that single-use drill can provide

better implant bed preparation, which might prevent bone loss. The micro-rings around the neck of the Seven implant seem to provide better bone fixation than does a polished surface.

Conclusion

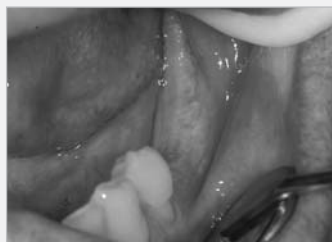With 72 implants inserted in mandibular terminal edentations, we can conclude that the Seven implants are better at maintaining the crestal bone level around implants. Further investigation will be done to see if the bone level remains stable over time.

References

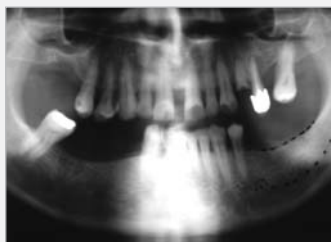- ¹A comparative prospective clinical study of two single-tooth implants: a preliminary report of 102 implants. Kemppainen P, Eskola S, Ylipaavainiemi P.
- ²Marginal bone reaction to oral implants: a prospective comparative study of Astra Tech and Brånemark System Implants. Per Astrand, Hartmut Feldmann, Bo Engquist, Simon Dahlgren, Eva Engquist, Kerstin Gröndahl. Clinical Oral Implants Research Volume 13 Page 30 - February 2002.
- ³Astra Tech and Brånemark system implants: a 5-year prospective study of marginal bone reactions. Per Astrand; Bo Engquist; Simon Dahlgren; Kerstin Gröndahl; Eva Engquist; Hartmut Feldmann. Volume 15, Number 4, August 2004.
- ⁴A 7-year follow-up of 93 Immediately loaded titanium dental implants. Marco Degidi, Adriano Piattelli, Journal of Oral Implantology, Vol. XXX/No. One/2005.
- ⁵Finite element analysis of an osseointegrated stepped screw dental implant. J. P. Peng W. Xu, B. Eng. B. C. Tan, G. R. Liu, Journal of Oral Implantology, Vol. XXX/No. Four/2004.
- ⁶A bone quality based implant system: first year of prosthetic loading. Carl E. Misch, Francine Dietsch-Misch, John Hoar, George Beck, Ray Hazen, Craig M. Misch. Journal of Oral Implantology, Vol. XXV/No. Three/1999.
- ⁷Aicrg, part ii: crestal bone loss associated with the ankylosis implant: loading to 36 months. Cherg-Tzeh Chou Harold F. Morris, MS Shigeru Ochi, Lori Walker, Deborah DesRosiers. Journal of Oral Implantology, Vol. XXX/No. Three/2004.
- ⁸Functional and esthetic considerations for single-tooth ankylosis implant-crowns: 8 years of clinical performance. Katrin Doring, Eduard Eisenmann, Michael Stiller. Journal of Oral Implantology, Vol. XXX/No. Three/2004.
- ⁹Imaging of peri-implant bone levels of implants with buccal bone defects: a radiographic and histometric accuracy study, by H. Schliephake, M. Wichmann, F. Donnerstag, S. Vogt. Clin Oral Implant Res, 14:193-200, 2003.

Case 2

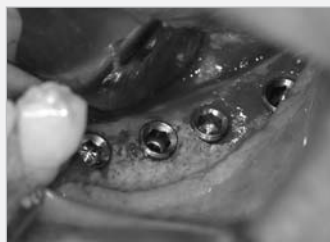Sixty-one-year-old male patient, nonsmoking and with good oral hygiene, with lower left mandibular edentulism; received four dental implants, two Seven implants in place of 35 and 37 and two Lance implants in place of 36 and 38.



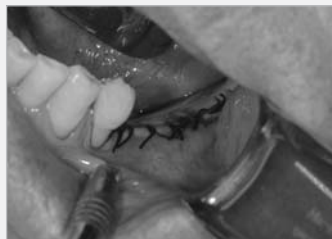Clinical view of the patient.



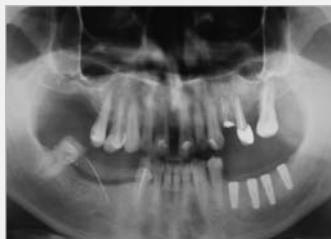Radiographic aspect of the bone offer.



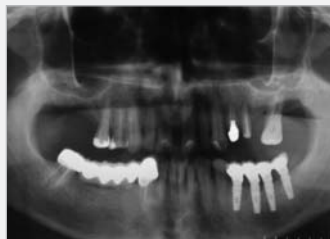Implants inserted.



Wound closure.

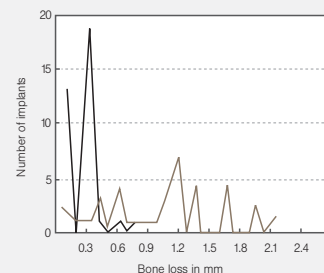


Radiographic view after surgery.

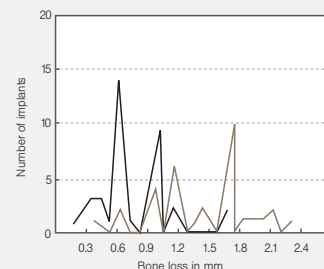


Radiographic view 6 months after loading.

Bone level 4 months after placement



Bone level 6 months after loading





0483 | ISO 9001:2000
ISO 13485:2003
FDA cleared for marketing

Authorized European Representative:
MIS Germany, Heidestrasse 7, 32427 Minden, GERMANY

© MIS Corporation. All rights Reserved.



MIS Implants Technologies Ltd.
www.mis-implants.com