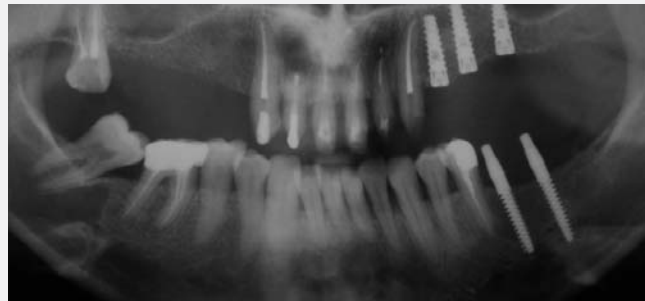

20

News No.20 February 2008

Soft Tissue Healing
Around One Piece (UNO)
with Full Rough-Treated
Implants: A Clinical Study.



mis
Make it Simple

Soft Tissue Healing Around One Piece (UNO) with Full Rough-Treated implants: A Clinical Study

Prof. Emanuel A. Bratu, Dr. Olimpiu L. Karancsi, Dr. Radu Sita

Department of Implant restorations, University of Medicine and pharmacy, Timisoara, Romania.

Purpose - To evaluate the capability of soft tissue healing around treated surface in one piece screw implants. **Materials and Methods** - In six patients with limited bone offer (class b), but with adequate bone height (minimum 10mm), 12 implants were evaluated both immediately after placement, and three months later, after loading. One group was treated with immediate restorations, while another was left three months for tissue integration before receiving superstructures. Peri-implant probing was performed after insertion and healing. **Results** - There were no significant differences between the two groups. All implants had good integration despite being inserted in different areas of the maxilla and mandible. Bone level around the implants showed a minimal decrease until the first threads. **Discussion** - The bone offer of patients differs significantly in quantity and quality, and soft tissue follows the pattern of these structures. Very often, patients refuse augmentative procedures, which are costly and sometimes involve major risk factors. Therefore, the use of one piece implants with reduced diameter, is still a treatment option even today, in the era of subgingival healing. One of modern implant dentistry's biggest problems is maintaining soft tissue around dental implants, particularly in the aesthetic zone. Implant

design has considerable influence on bone and soft tissue levels, as shown in different studies. Several methods of soft tissue management have evolved over the last few decades, with an emphasis on soft tissue transpositions and transplants. However, these procedures are not always within reach of the general practitioner. In the last five years, the polished neck of dental implants has been losing ground to treated surfaces. Until now, most studies concentrated on bone level around implants. The aim of this study was to evaluate the adherence and behavior of soft tissue around a treated surface, in one piece transgingival implants. **Conclusion** - Soft tissue healing around a rough surface was eventless, with no irritation or bleeding. No significant tissue retraction was observed after three months. The results suggest that there is no need for a polished surface at the implant neck in order to prevent tissue irritation.

Materials and Methods

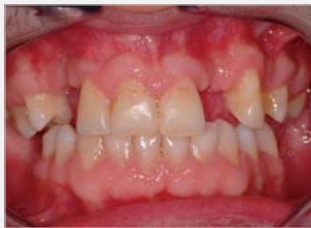The study comprised six patients, each of whom received one or two one piece full rough-treated covered MIS (Shlomi-Israel) screw implants, of 10-13mm length, and 3mm diameter, in different regions of the mouth.

Basic evaluation included medical history, smoking habit evaluation, extra-and intraoral examination, and radiographic panoramic examination. During these investigations, bone and soft tissue quantities were estimated. Patients with sufficient bone quantity were selected. A minimum of 4mm bone width, and 11mm bone height was necessary in order to insert the implants. Surgery was performed using local anesthesia (Ultracain DS Forte, Aventis Pharma).

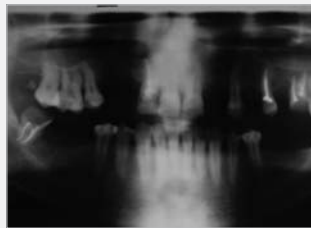
Surgical Procedure

A crestal incision was performed, and full mucoperiosteal flaps were elevated in the areas of implant insertion. Bone was cleaned of periosteal tissue, and markings of implant position were performed with a round bur. Then a 2mm pilot drill marked the depth and angulation of the implant. For the first 2mm depth, in cortical crestal bone, a 2.80mm enlargement drill was used. Implants were inserted using a ratchet until the final position was reached. This position was considered to be right below the abutment, with the threads completely covered by bone. Medication included antibiotics (Augmentin 1gr SmithKline Beecham) for six days and analgesics (Ketonal forte, 200mg) for three days. Probing depths

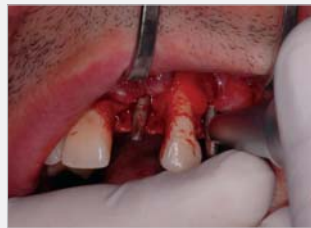Clinical case presentation: **Case 1**



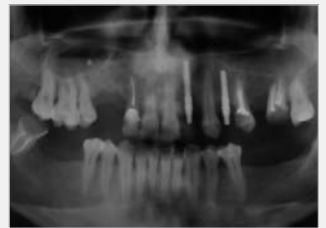1. Oral status at first visit



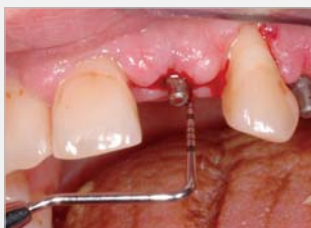2. Panoramic X-ray with the initial status



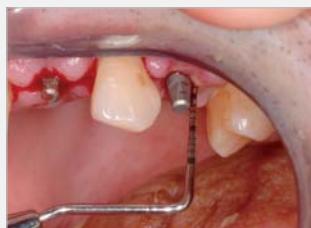3. Periosteal measurements after insertion



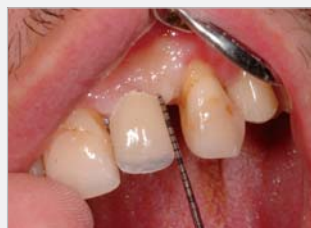4. Panoramic X-ray after insertion



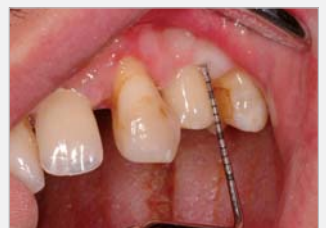5. Probing depth after suture removal for implant 22



5b. Probing depth after suture removal for implant 24



6. Probing depth after 3 months with provisional restoration in place implant 22



6b. Probing depth after 3 months with provisional restoration in place implant 22

around the implants were performed after suture (Silk, 4-0, B. Braun). Periotest measurements were taken after insertion, with values between from 02 to -04.

Follow-Up And Examination

Patients returned after three days and depending on periotest values, a decision was made to either perform immediate restoration or allow for a healing time period. Half the patients(those with negative periotest values) received provisional restorations; half (those with positive values) did not. The immediate restorations were made of acrylic resin and cemented with provisional Temp-Bond cement (Kerr).

For the patients who waited three months, another probing depth measurement was taken after the healing period and compared to that on the day of surgery. Both patient groups were instructed to use good hygiene and to eat only soft foods for two weeks following their visit. No implant was lost during the test. All patients presented fixed, healed gingiva around the implants. The group with provisional restorations showed even more rapid and better healing compared to the group with no restorations.

Results

The six patients comprised four men and two women, with a mean age of 48 years (and a range of 37 to 60 years). All patients presented small edentulous spaces, no total tooth loss. Probing depth values varied from 2mm to 4mm at suturing, and from 1mm to 2mm after three months. No bleeding was observed. There was no significant difference between male and the female patients. Patients with thick peri-implant tissue presented smaller depths compared to those with a thin layer of soft tissue. In each case, we tried to obtain fixed gingiva around the implants; otherwise, the probing depths would have made no sense. This confirms the theory of fixed keratinized gingiva around implants.

Discussion

The present clinical study evaluated the stabilization of soft tissue around full rough treated surface. At the initial examination after implant insertion, probing depths showed greater values comparing to the values obtained after three months. This is normal because of the healing process of

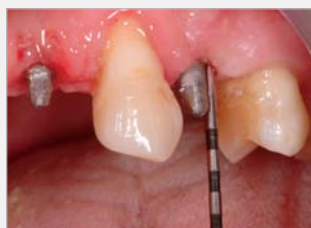the peri-implant tissues. Of clinical value is the fact that during the healing period there was no irritation of the soft tissue around the implants. This suggests that whether or not a patient receives a provisional, if certain criteria are accomplished the gingiva recovers well and adheres on a rough surface.

Conclusion

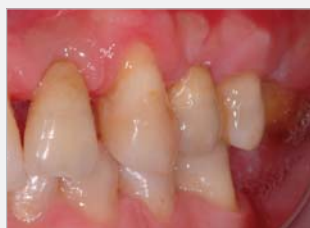The study demonstrated that if fixed gingiva around the implant can be obtained, there is no absolute need for a polished implant neck in order to prevent peri-implant tissue irritation. Also, if the pocket depth depends on the thickness of the mucosa, then thicker the mucosa, the smaller the depth. However, if the gingiva is not fixed, plaque deposits problems can arise, and implant failure is possible. Initial results are promising, but further investigation and longer observation periods are needed in order to make a definitive statement on this issue.

Nr	Age	Sex	Size	Position	Periotest value	Probing depth	
						Insertion	3 months
1	45	F	3/13	36	-1	4	2
			3/13	37	0	3	1.5
2	50	M	3/13	43	-3	3	1.5
3	47	M	3/10	12	+1	3.5	2
4	62	M	3/13	45	-4	4	2
5	51	M	3/10	22	+2	4	1.5
			3/13	24	+1	3	2
6	37	F	3/10	14	0	3	1

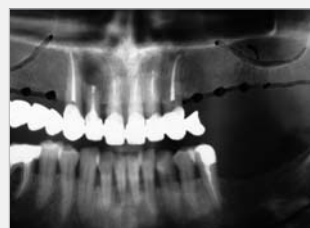*All patients presented a fixed healed gingiva around the implants



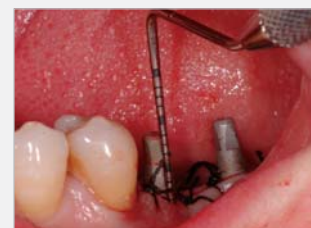7. Probing depth before cementing final restoration implant 24



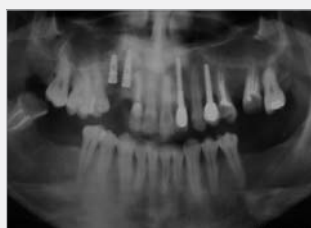8. Final restoration in place



1. Panorami x-ray at patient presentation



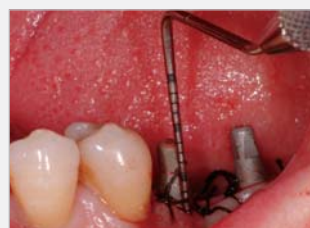2. Probing depth after suturing implant 37



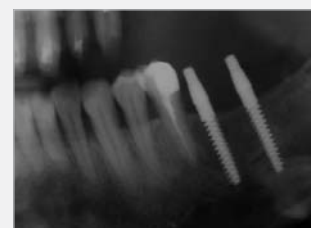
9. Panoramic X-ray after final restoration setting



10. One piece (UNO) in Panoramic X-ray



3. Probing depth after suturing implant 36



4. Panorami X-ray after impalant insertion

Case 2



0483 | ISO 9001:2000
ISO 13485:2003

Authorized European Representative:
MIS Germany, Paulinenstraße 12a, 32427 Minden, GERMANY

© MIS Corporation. All rights Reserved.



MIS Implants Technologies Ltd.
www.mis-implants.com