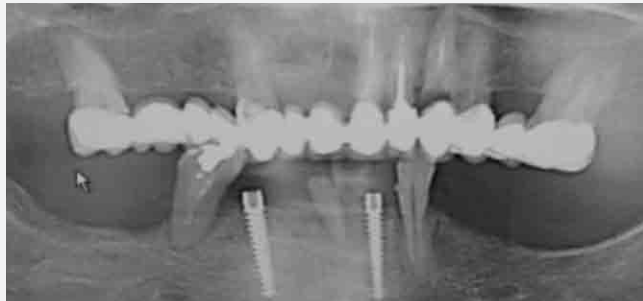


21

News No. 21 December 2008

3mm UNO Narrow Implant: A Preliminary Study on Human Mandible.

*Using UNO Narrow Implant, MIS, Shlomi



MIS
Make it Simple

3mm UNO Narrow Implant: A Preliminary Study on Human Mandible.

Dr. Luca Di Alberti DDS, PhD

Introduction

Edentulous patients with severe residual ridge resorption frequently complain about poorly fitting, loose dentures, even if these were manufactured according to the state of the art. This problem is caused by level or only slightly raised alveolar ridges, which allow undesirable shifting of the dentures even when only minor horizontal forces are applied.

Implant-supported dentures can lead to considerable improvement by preventing horizontal shifting and stabilizing the restoration. However, narrow denture bearing areas with equally narrow firmly attached gingival often necessitate supplementary therapy.

Restorative therapy of edentulous mandibles with residual horizontal and vertical ridge resorption is still a great challenge.

Even though implant-supported stabilization of dentures has proved to be of value in these cases, treatment is sometimes problematic, not only due to narrow width of the denture-bearing areas but also because elderly patients are often averse to surgery.

Implants with a normal length but a reduced diameter might facilitate therapy in patients with implant-supported dentures. The aim of the present study was to evaluate the clinical success of implants with a small diameter.

Methodology and results

Eight 3mm conical screw implants (UNO Narrow Implant, MIS, Shlomi) have been inserted in the lower mandibles of healthy patients and checked for surgical procedures and implant stability.

The surgical procedure was performed using first a round burr for the whole body of it, then a 2mm cylindrical burr as pilot drill for the length of the implants and then the final drill with a diameter of 2.40mm. The site preparation was performed flapless for half of the implants and with flap elevation for the other four implants.

All implants were inserted manually with the plastic mounter for the first half of the implant and then with an hand wrench until

the complete insertion. A variable torque between 50 and 65N/Cm, depending on the quality of the bone, was used for complete insertion. A perfect primary stability was noted after the insertion.

The RFA value (Ostell) after insertion was between 60 and 68, and this confirmed the hypothesis of immediate loading of the 3mm implant in lower jaws with removable prostheses.

The implants are designed as two-stage implants. This is useful in cases of poor bone quality or post-extractive insertion where the primary stability is not high enough to support immediate loading.

The ball anchors have different transmucosal neck lengths for a better fitting of the removable denture. The interchangeable ball anchor is a great support for lifetime maintenance of the implants.

The single-piece implants with ball anchors currently on the market have a critical problem when the fitting loosens due to friction and none of the Teflon caps will fit properly.

Conclusions

1. The 3mm implant is extremely easy surgically and handy for the packaging.
2. The primary stability is high enough to support immediate loading.
3. The implant is designed as a two-stage implant but can also be used as a single-stage implant for immediate loading.
4. The ability to change the ball anchor provides both perfect stability and ease of maintenance in a removable denture.
5. The height of the ball anchor can be adjusted to accommodate changes in gum anatomy or other health changes, providing consistent comfort for the patient over the lifetime of the implant.

References

- Morneburg TR, Pröschel PA. Success rates of microimplants in edentulous patients with residual ridge resorption. *Int J Oral Maxillofac Implants.* 2008 Mar-Apr; 23(2):270-6.
- Flanagan D. Fixed partial dentures and crowns supported by very small diameter dental implants in compromised sites. *Implant Dent.* 2008 Jun; 17(2):182-91.
- Flanagan D. Immediate placement of multiple mini dental implants into fresh extraction sites: a case report. *J Oral Implantol.* 2008; 34(2):107-10.
- Misch K, Neiva R. Small-diameter implants for optimal stabilization of implant-supported overdentures. *Pract Proced Aesthet Dent.* 2007 Aug; 19(7): 428-31.
- Choi R. Incorporating mini-implants within the general dental practice. *Pract Proced Aesthet Dent.* 2007 Jul;19(6): suppl 1-5.
- Shatkin TE, Shatkin S, Oppenheimer BD, Oppenheimer AJ. Mini dental implants for long-term fixed and removable prosthetics: a retrospective analysis of 2514 implants placed over a five-year period. *Compend Contin Educ Dent.* 2007 Feb; 28(2): 92-9; quiz 100-1.
- Vigolo P, Givani A, Majzoub Z, Cordioli G. Clinical evaluation of small-diameter implants in single-tooth and multiple-implant restorations: a 7-year retrospective study. *Int J Oral Maxillofac Implants.* 2004 Sep-Oct; 19(5):703-9.
- El-Sheikh AM, Hobkirk JA, Howell PG, Gilthorpe MS. Passive tactile sensibility in edentulous subjects treated with dental implants: a pilot study. *J Prosthet Dent.* 2004 Jan;91(1):26-32.
- Bergendal T, Engquist B. Implant-supported overdentures: a longitudinal prospective study. *Int J Oral Maxillofac Implants.* 1998 Mar-Apr; 13(2): 253-62.

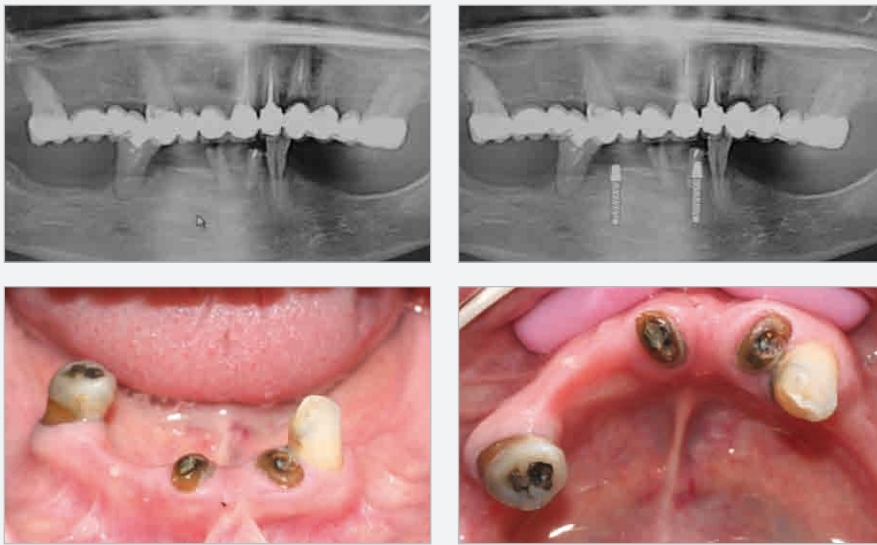


Fig.1: Presurgical X-ray, treatment planning on OPT and clinical view at first visit.

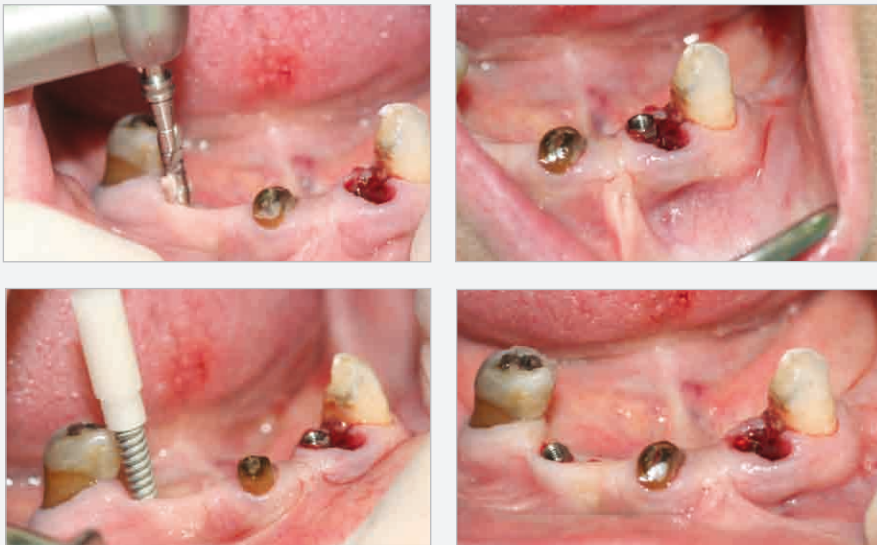

Fig.2: Surgical procedures and implant insertion.

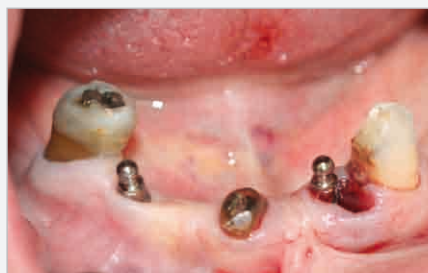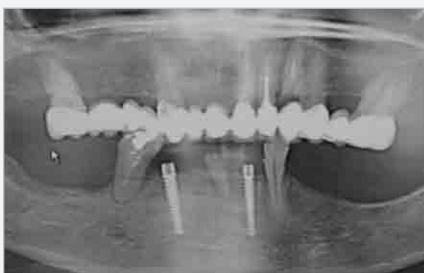

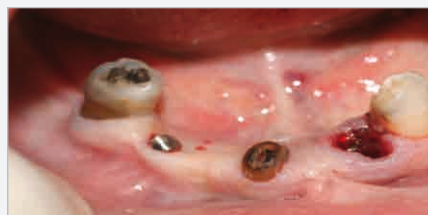
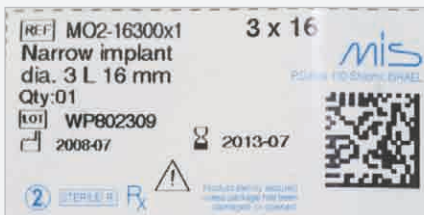Fig.3: Implant information, implants inserted, postoperative X-ray control and ball anchors attached.

MIS's Quality System complies with international quality standards: ISO 13485:2003 - Quality Management System for Medical Devices, ISO 9001:2000 - Quality Management System and CE Directive for Medical Devices 93/42/EEC. MIS's products are cleared for marketing in the USA and CE approved.

© MIS Corporation. All rights Reserved.

The logo for MIS (MIS Implants Technologies Ltd.) features the lowercase letters 'mis' in a white, sans-serif font. The 'i' has a vertical line extending upwards from its top, and the 's' has a horizontal line extending to the right, ending in a small hook. A registered trademark symbol (®) is positioned to the upper right of the 's'.

MIS Implants Technologies Ltd.
www.mis-implants.com